

Argulus foliaceus (Crustacea: Branchiura) Infestation on Oscar, *Astronotus ocellatus* (Cuvier, 1829) and Its Treatment

Erol Tokşen

Ege University, Faculty of Fisheries, Department of Aquaculture, Bornova, 35100, Izmir, Turkey
E mail: erol.toksen@ege.edu.tr

Özet: *Astronot balıklarında* (*Astronotus ocellatus* Cuvier, 1829) *görülen Argulus foliaceus* (Crustacea: Branchiura) enfeksiyonu ve tedavisi. Balık biti olarak da adlandırılan *Argulus foliaceus* tatlı su balıklarının deri ve solungaçlarında parazit olarak yaşamaktadır. Hasta balıklar havuz duvarına ve diğer cisimlere sürtünme gibi belirtiler gösterir. Balık, enfeksiyonun ilerlemiş evrelerine kadar yem almaya devam eder. Bu çalışmada, bir akvaryumcudan alınan anormal yüzen, zayıf ve ölmek üzere olan astronot balıkları (*Astronotus ocellatus*) bakteriyel, parazitler ve fungal hastalıklar açısından incelendi. Herhangi bakteriyel bir hastalık teşhis edilmedi. Balığın deri ve solungaçlarında görülen parazitin *A. foliaceus* olduğu tespit edildi. DDVP (dichlorvos, 0,0-dimeethyl-0-2,2-dichloro vinyl phosphate)'nin *A. foliaceus*'a karşı etkili olup olmadığını anlamak için tedavi denemeleri yapıldı. *A. foliaceus* ile enfekte 450 g. ağırlığında 25 cm boyunda 40 adet *A. ocellatus* 250 litrelik tanklara konuldu. Denemeler 26°C su sıcaklığında yapıldı. DDVP 1 ppm dozunda 1 saat uygulandı. Uygulama sonrasında tüm balıklar parazit açısından incelendi. Balıklar üzerinde parazit görülmedi. Önceden var olan semptomlar tedavi sonrasında kayboldu.

Anahtar Kelimeler: *Astronotus ocellatus*, *Argulus foliaceus*, parazit, DDVP, tedavi.

Abstract: *Argulus foliaceus*, or the fish louse, parasitize the skin or gill of the fresh water fish species. Clinical signs in infected fish include scratching or flashing on pond walls or other objects. The fish will continue to eat until the advanced stages of infestation. In the present study, *Astronotus ocellatus* species (tiger oscar) taken from a local pet shop with symptoms such as abnormal swimming, poor growth and moribundity were examined for bacterial, fungal and parasitological infections. Any pathogen bacteria were isolated. The parasites observed on the skin and fins of fish were identified as *A. foliaceus*. Then, treatment trials were conducted to evaluate of DDVP (dichlorvos, 0,0-dimeethyl-0-2,2-dichloro vinyl phosphate) against to *A. foliaceus*. Trials were carried out at water temperature of 26 °C. Fourty specimens of *A. ocellatus* infested with *A. foliaceus*, with mean weights 450 g and mean length 25 cm. were held in experimental tanks of 250 l. 1 ppm of DDVP administered to tanks during 1 hour. After administration, all fish were checked for parasite. No parasite was observed on the fish. The symptoms observed before, disappeared after treatment.

Key Words: *Astronotus ocellatus*, *Argulus foliaceus*, parasite, DDVP, treatment.

Introduction

The genus *Argulus* spp. (Crustacea: Branchiura), or fish louse, are 5-10 mm in size and found nearly worldwide with about 150 species known at present. (Bykhovskaya-Pavlovskaya 1964, Bauer 1991).

Three species documented in Europe which are *Argulus foliaceus*, *A. japonicus* and *A. coregoni*. *A. foliaceus* also occurs on brown trout, as well as perch, tench, carp, pike and bream (Gurney 1948).

The general body-form of *Argulus* is a dorso-ventrally flattened and covered by a large chitinous carapace. The body can be divided into 3 distinct regions: cephalothorax; thorax and abdomen (Soulsby 1982, Fryer 1982, Lester and Roubal 1995).

Argulus spp. have direct life cycle described by several authors (Shimura 1983, Mikheev et al. 2001). Parasitic larva must find a host within the first 2-3 days after hatching otherwise they will perish (Kollatsch 1959).

The direct effects of this parasite on its host depend on the number of parasites and the size of the host. One or two parasites on a small fish cause the local damage on the

epithelia. Several parasites have a very significant effect. Fish with heavy infestations become lethargic, can cease feeding and show a general deterioration in their condition as reduced pigmentation, fins drooping (Lester and Roubal 1995).

As well as the damage and stress caused by *Argulus* itself, one of the main worries for fish producers is the associated secondary infestations that can result from infestations with parasite. Several studies have examined the role of parasites as vectors for other diseases such as Aeromoniasis or Pseudomoniasis (Bauer 1991, Richards 1977).

There are many methods of control, prevention and treatment of argulosis (Puffer and Beal 1981, Kabata 1985, Singhal et al. 1986, Poulin and FitzGerald 1987, Gault et al. 2002, Hakalahti et al. 2004).

In this study, *A. foliaceus* infestation of tiger oscar (*A. ocellatus*) and their treatment is discussed.

Materials and Methods

The research material consisted of 30 tiger oscar (*Astronotus ocellatus*) (450 g in weight and 25 cm in length). Fish samples

were weighed, measured and thereafter body surface, gill, body cavity and internal organs were examined for bacterial, fungal and parasitical enfections.

The specimens taken out from kidney, liver and spleen of moribund fish were cultured on Tryptoe Soya Agar (TSA-Difco), Anacker & Ordal's Agar (AOA) and incubated at 20-22 °C 5 days for bacterial investigations.

The parasites which picked up were fixed in 70% ethyl alcohol and identified morphologically following keys characteristics given by Bykhovskaya-Pavlovskaya et al. (1964).

Treatment trials were carried out at water temperature of 26 °C in aerated 500 l tanks. Feeding was stopped one day before the treatment. 1 ppm of DDVP administered to tank for 1 hour. DDVP bath repeated 21 days later to treat the emerging larvae and juveniles. Because the symptoms were reappeared three weeks later.

Results

Fish infested with *A. foliaceus*, had brown-grey points on the skin and fins due to parasitic irritation and tissue damage. Parasites were collected from around the operculum, fins and body surface. The mean number of parasites per fish was 10-13. The dimensions were 2838-4158 x 1782-2805 µm in size (Fig. 1). The parasite has rounded lobes of abdomen and the posterior emargination not reaching the mid-line and posterior lobes cephalothoracic carapace not extended beyond the beginning of abdomen (Fig. 2). The parasite identified as *A. foliaceus* by the looking morphologic key characteristics under the light microscope.

During treatment, neither adverse effects nor mortality were observed during the DDVP bath. All fish were checked in term of parasite following the treatment. No parasite was observed on the fish. But the symptoms were reappeared 3 weeks later. Because the larvae emerged from eggs did not be affected from drug transformed into juvenil and then into adult stages. The drug administrated again at same dose.

Discussion

Argulus sp. was reported from different fish species worldwide (Buchmann and Bresciani 1997, Molnar and Szekeley 1998) and also from some freshwater fish species in Turkey (Geldiay and Balık 1974, Sarieyyüpoğlu and Sağlam 1991). In the present study, *A. foliaceus* was reported from *A. ocellatus*.

A. foliaceus infestations cause the skin irritation manifested by flicking of the fins (Richards 1977, Bauer 1991). This is often accompanied by increased mucus production over the skin surface and the appearance of small haemorrhages (Richards 1977). In this study, abnormal swimming, rubbing themselves against the wall of tank and lack of appetite were observed in diseased fish. The skin and fins have numerous brownish grey points and hemorrhagic areas.

It is known that *Argulus* infestations lead to secondary

parasitic infestation of the skin (Soulsby 1982, Bauer 1991). Some authors reported that *Costia necatrix* accompanied by *A. foliaceus* in infected fish, and also *Trichodina sp.*, *Trichodinella sp.* and *Apiosoma sp.* were observed in skin and gills preparation (Bauer 1991, Burgu and Oğuz 1984). In this study, no other parasites were observed on the body surface and gill.

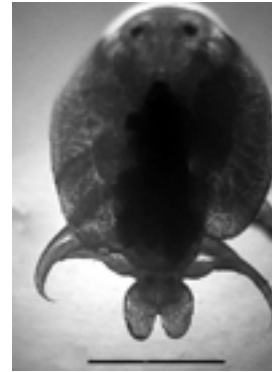


Figure 1. Total parasite. Bar: 1.5 mm.

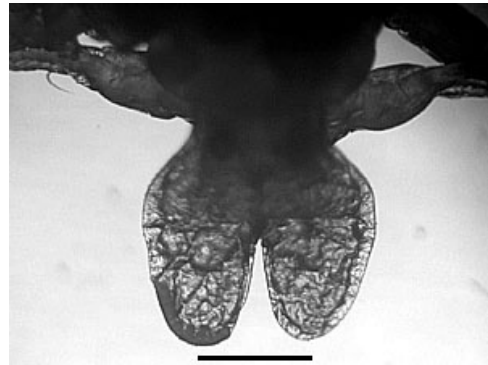


Figure 2. Caudal part of parasite. Bar: 0.4 mm.

The number of parasite on each fish may be different. Fryer (1982) reported thousands of *Argulus* species occurring on a single tench. In this study 13 *A. foliaceus* were counted on an individual tiger oscar. This might be related to the early stage of infection. Pathogenesis was not severe because these fish were big and a few parasites being found on the fish.

Treatment of *Argulus* species is accomplished using organophosphates, potassium permanganate (2-5 mg/l, bath) or dimilin (0.01 mg/l, bath) (Öge 2002). The most effective treatment against Argulosis is with organophosphates (Bauer 1991). Organophosphates, usually 2-3 doses at one week intervals, are needed to treat the emerging larvae and juveniles. Other chemicals used for treatment of *Argulus* was pyrethrum (20-100 ppm for 10-20 minutes); malathion (0.25 ppm for 6 hours); dipterex (100 ppm for 1 hour); trichlorfon (0.25 ppm for several hours); quinine hydrochloride (13.5 ppm for several days); atebine (10 ppm for several days) (Kabata 1985); DTHP (2.5 ppm 1 hour) (Puffer and Beal 1981). Recently Hakalahti et al. (2004) used the emamectin

benzoate for the control of *A. coregoni* and observed that the drug was very effective.

In the present study, treatment of fish with DDVP (1 ppm) administered. The bath was repeated after three week and was found to be effective.

References

- Bauer, R. 1991. Erkrankungen der Aquarienfische. Verlag Paul Parey, Berlin und Hamburg.
- Buchmann, K., J. Bresciani. 1997. Parasitic infections in pond-reared rainbow trout *Oncorhynchus mykiss* in Denmark. Inter-Reseach. Dis. Aquat. Org., 28: 125-138.
- Burgu, A., T. Oguz. 1984. The results of parasitological examination of Carassius fish. (in Turkish) Ankara Univ. J. Vet. Faculty., 31: 197-206.
- Bykhovskaya-Pavlovskaya, I.E., A.V. Gusev, M.N. Dubinina, N.A. Izyumova, T.S. Smirnova, I.L. Sokolovskaya, G.A. Shtein, S.S. Shulman and V.M. Epstein. 1964. Key to Parasites of Freshwater Fish of the U.S.S.R. Leningrad.
- Fryer G. 1982. The Parasitic Copepoda and Branchiura of British Freshwater Fishes: A handbook and key. Freshwater Biological Association, Scientific Publication, 46.
- Gault, N.F.S., D.J. Kilpatric and M.T. Steward. 2002. Biological control of the fish louse in a rainbow trout fishery. J. Fish Biol., 60: 226-237.
- Geldiay, R., S. Balik. 1974. Mainly endo and ecto-parasites observed on the fresh water fish in Turkey (in Turkish). Ege Üniv. Matbaasi, İzmir.
- Gurney, R. 1948. The British species of fish-lice of the genus *Argulus*. Proceedings of the Zoological Society of London, 118: 553-558.
- Hakalahti, T., Y. Lankinen and E.T. Valtonen. 2004. Efficacy of emamectin benzoate in the control of *Argulus coregoni* (Crustacea: Branchiura) on rainbow trout *Oncorhynchus mykiss*. Dis Aquat Org., 60: 197–204.
- Kabata, Z. 1985. Parasites and Diseases of Fish Cultured in the Tropics. Taylor & Francis, London.
- Kollatsch, D. 1959. Untersuchungen über die Biologie und Ökologie der Karpfenlaus (*Argulus foliaceus* L.). Zool Beitr., 5:1–36.
- Lester, R.J.G., F. R. Roubal. 1995. Phylum Arthropoda, p. 475-598. In P.T.K. Woo [ed], Fish Diseases and Disorders, Volume 1: Protozoan and Metazoan Infections. CAB International, Wallingford, U.K.
- Mikheev, V.N., A.F. Pasternak, E.T. Valtonen, Y.A.N. Lankinen. 2001. Spatial distribution and hatching of overwintered eggs of a fish ectoparasite, *Argulus coregoni* (Crustacea: Branchiura). Dis Aquat Org., 46: 123–128.
- Molnar, K., C. Szekely. 1998. Occurrence of skrjabillanid nematodes in fishes of Hungary and in the intermediate host, *Argulus foliaceus* L. Acta Vet. Hun., 46: 451.
- Oge, S. 2002. Chemotherapy for parasites of freshwater fish. J. Turkish Parazitol., 26: 113-118.
- Poulin, R., G.J. FitzGerald. 1987. The potential of parasitism in the structuring of salt marsh stickleback community. Canadian J. Zool., 67: 14-18.
- Puffer, H.W., M.L. Beal. 1981. Control of parasitic infestations in killifish (*Fundulus parvipinnis*). Lab. Animal Sci., 31: 200-201.
- Richards, R. 1977. Diseases of aquarium fish-2.Skin diseases. Vet. Rec., 101 : 132-135.
- Sarıeyyupoglu, M., N. Sağlam. 1991. *Ergasilus sieboldi* and *Argulus foliaceus* observed on *Capoeta trutta* caught in the polluted region of Keban Dam Lake (in Turkish). E.Ü. Su Ürün. Derg., 8: 143-154.
- Shimura, S. 1983. Seasonal occurrence, sex ration and site preference of *Argulus coregoni* Thorell (Crustacea:Branchiura) parasitic on cultured freshwater salmonids in Japan. Parasitology, 86: 537-552.
- Singhal, R.N., S. Jeet and R.W. Davies. 1986. Chemotherapy of six ectoparasitic diseases of cultured fish. Aquacult. and Fish. Manang., 54: 175-171.
- Soulsby, E.J.L. (1982) Helminths, Arthropods and Protozoa of Domesticated Animals. 7th Ed. Baillière Tindall, London, U.K.